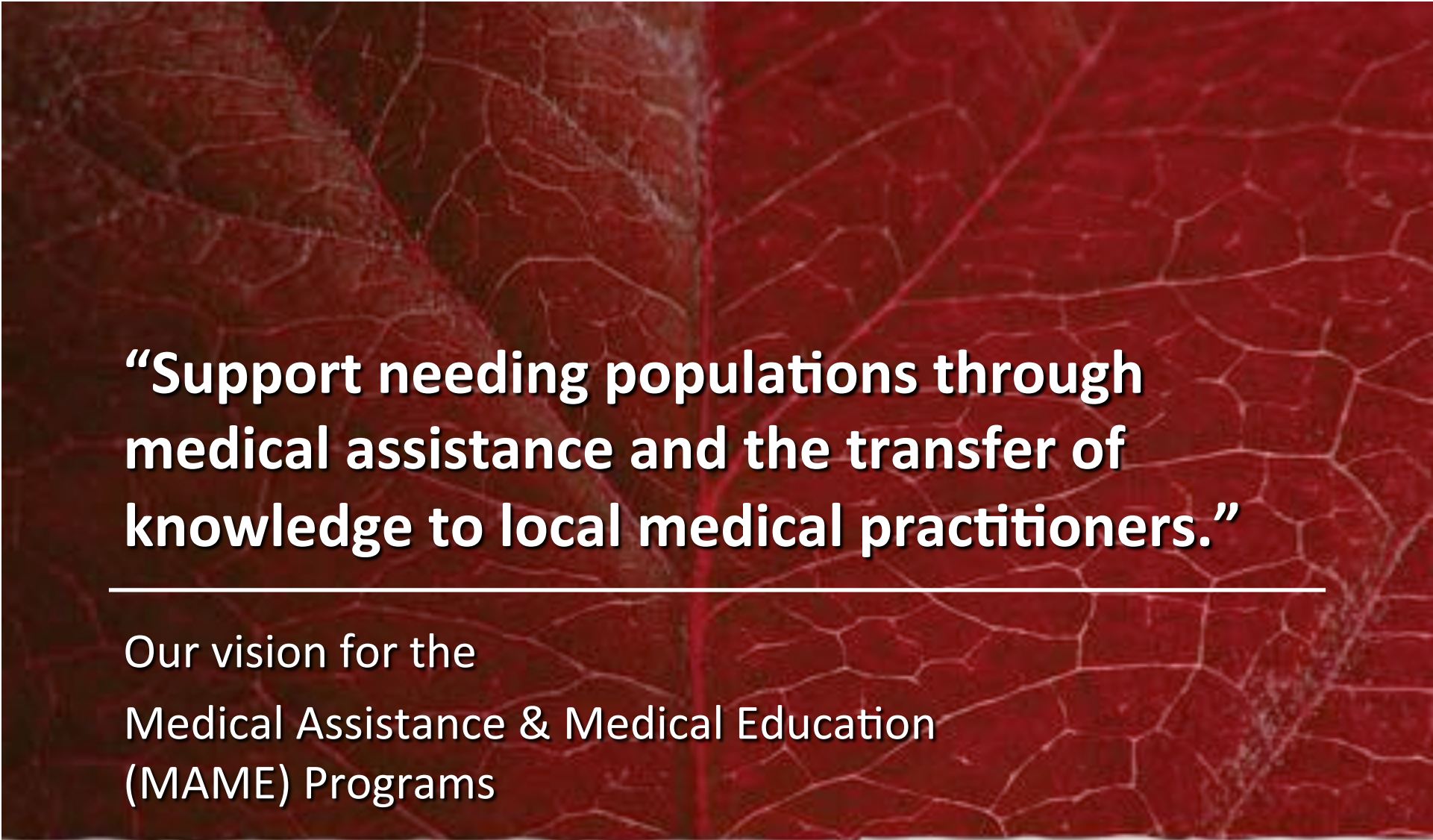


CMV Retinitis

Dr. NI NI TUN

Medical Action Myanmar

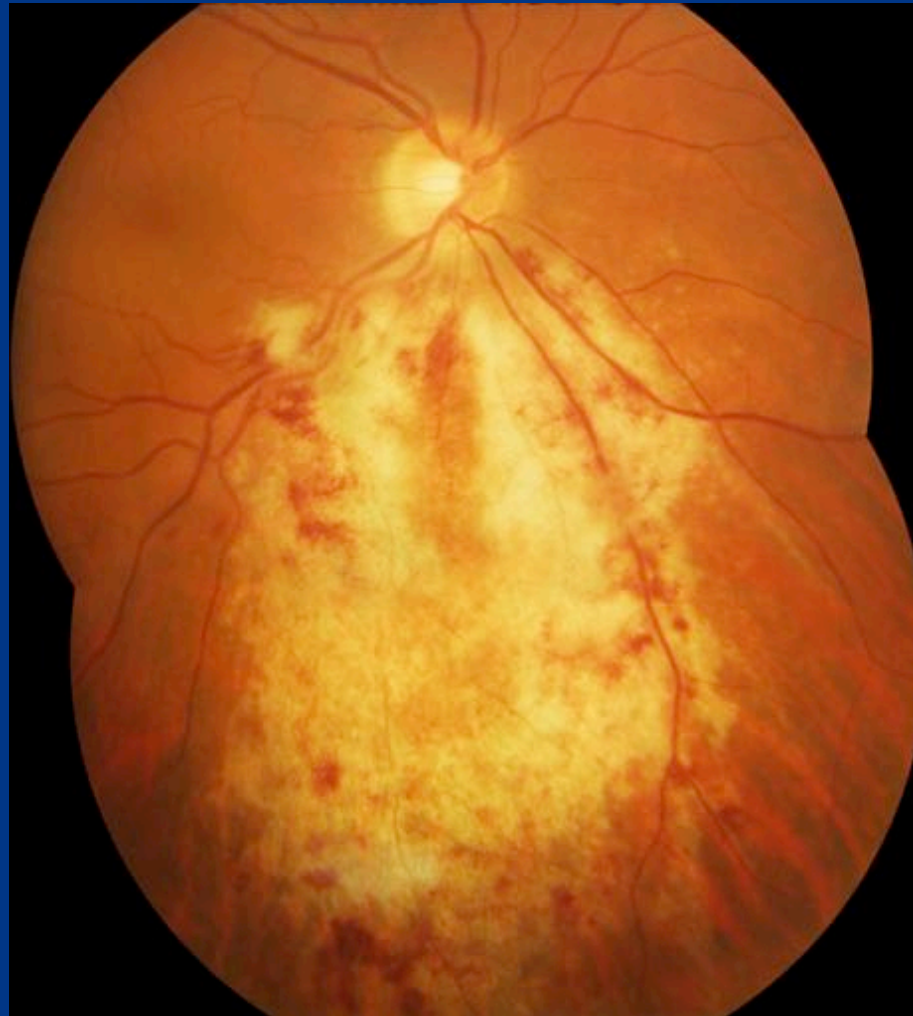

“Support needing populations through medical assistance and the transfer of knowledge to local medical practitioners.”

Our vision for the
Medical Assistance & Medical Education
(MAME) Programs

GreenShoots
FOUNDATION

CMV Retinitis



CMV epidemiology

- There is >90% sero-positivity for CMV in the developing world.
- It is the most common opportunistic infection of the eye and accounts for over 90% of HIV-related blindness.
- In resource-limited settings, CMV retinitis is the only clinical manifestation of CMV disease that we can diagnose.
- In the USA, pre-ART, there was a 2%/month (24%/year) incidence of CMV retinitis in patients with CD4<50 cells
(*NEJM 1996 June 6;334(23):1491-7.*)

CMV retinitis epidemiology

- CMV retinitis is arguably the most neglected disease of the AIDS pandemic (5). It remains largely undiagnosed and untreated in most resource-limited settings, and therefore determining the true prevalence is difficult.
- Cambodia, Myanmar, Thailand [2007];
 - 25% of patients with $CD4 < 50$ had CMV retinitis (5).
 - 33-44% was asymptomatic
- A recent review found that the prevalence of CMV retinitis in resource-limited settings, notably Asian countries, remains high (6).

CMV

- Many late presenting HIV positive patients die of CMV or are left permanently blind, many at young age, from undiagnosed or inadequately treated cytomegalovirus retinitis.

CMV retinitis in high income countries

- Diagnosis with indirect ophthalmoscope
- Treatment with
 - systemic anti-CMV treatment (oral valganciclovir),
 - +/- intraocular ganciclovir.

CMV retinitis in resource limited settings

- Diagnosis; Indirect ophthalmoscopy rarely performed.
- Usually no diagnosis and no treatment

- In Thailand (National protocol) and some projects in Cambodia, China and Myanmar,
 - Oral valganciclovir too expensive
 - Ganciclovir eye injection to prevent blindness.
 - When patients get ART, it is hoped that the immune system will recover soon enough to prevent mortality from extra-ocular CMV disease.

A CMV retinitis project in Myanmar and Cambodia, China, South Africa, Thailand and Uganda

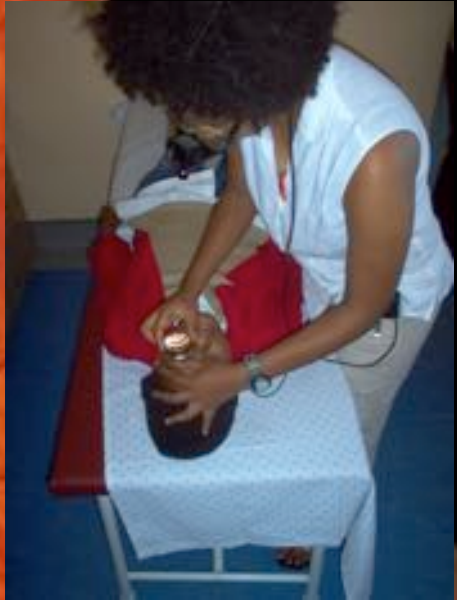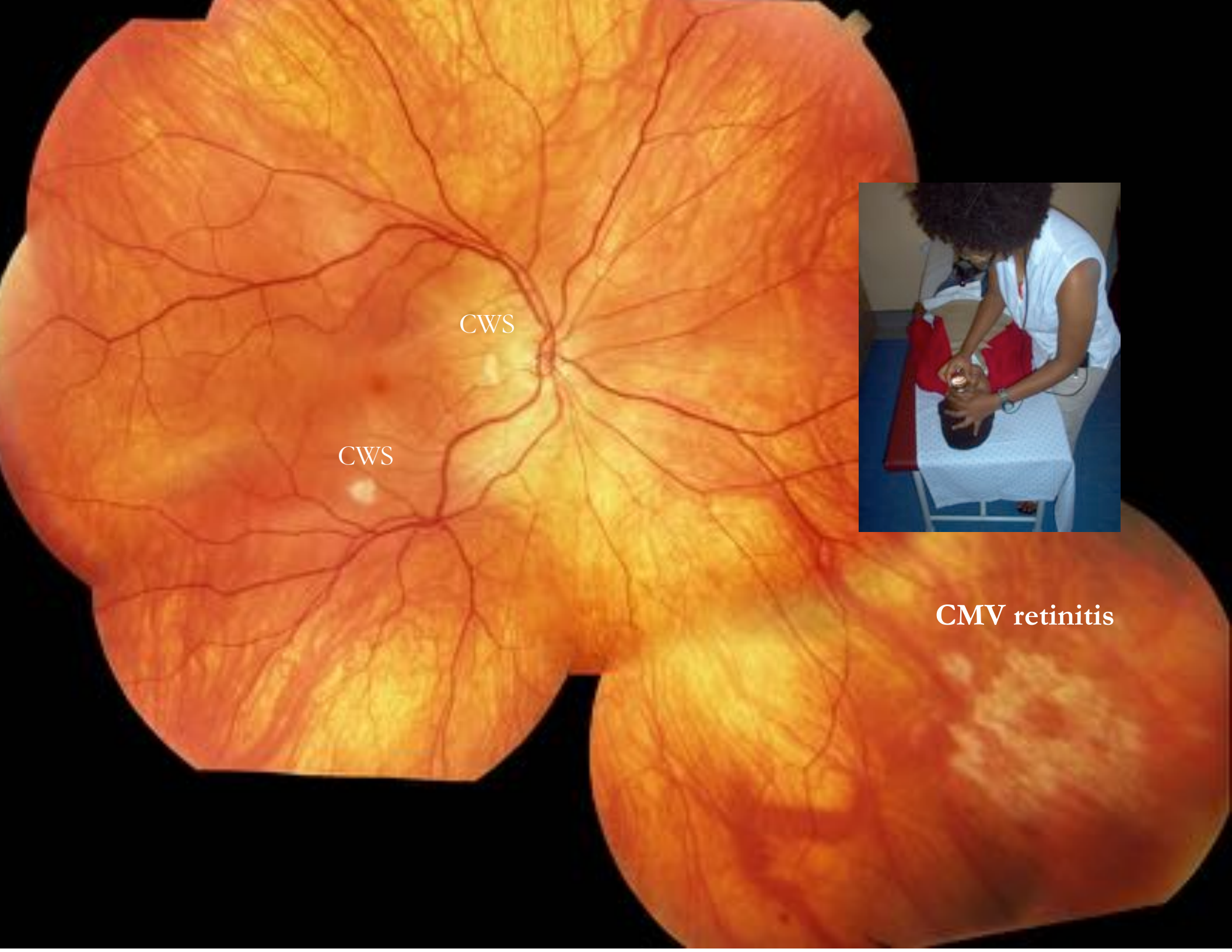
- David Heiden (Ophthalmologist) trained since 2006 yearly 6 HIV clinicians (for 1 week) in indirect ophthalmoscopy and intraocular injections
- Evaluation of training by a variety of methods documented high clinical competence.
- Systematic screening of all high-risk patients (CD4 <100 cells/mm³) was carried out in 10 separate AIDS clinics throughout Myanmar.

Diagnosis

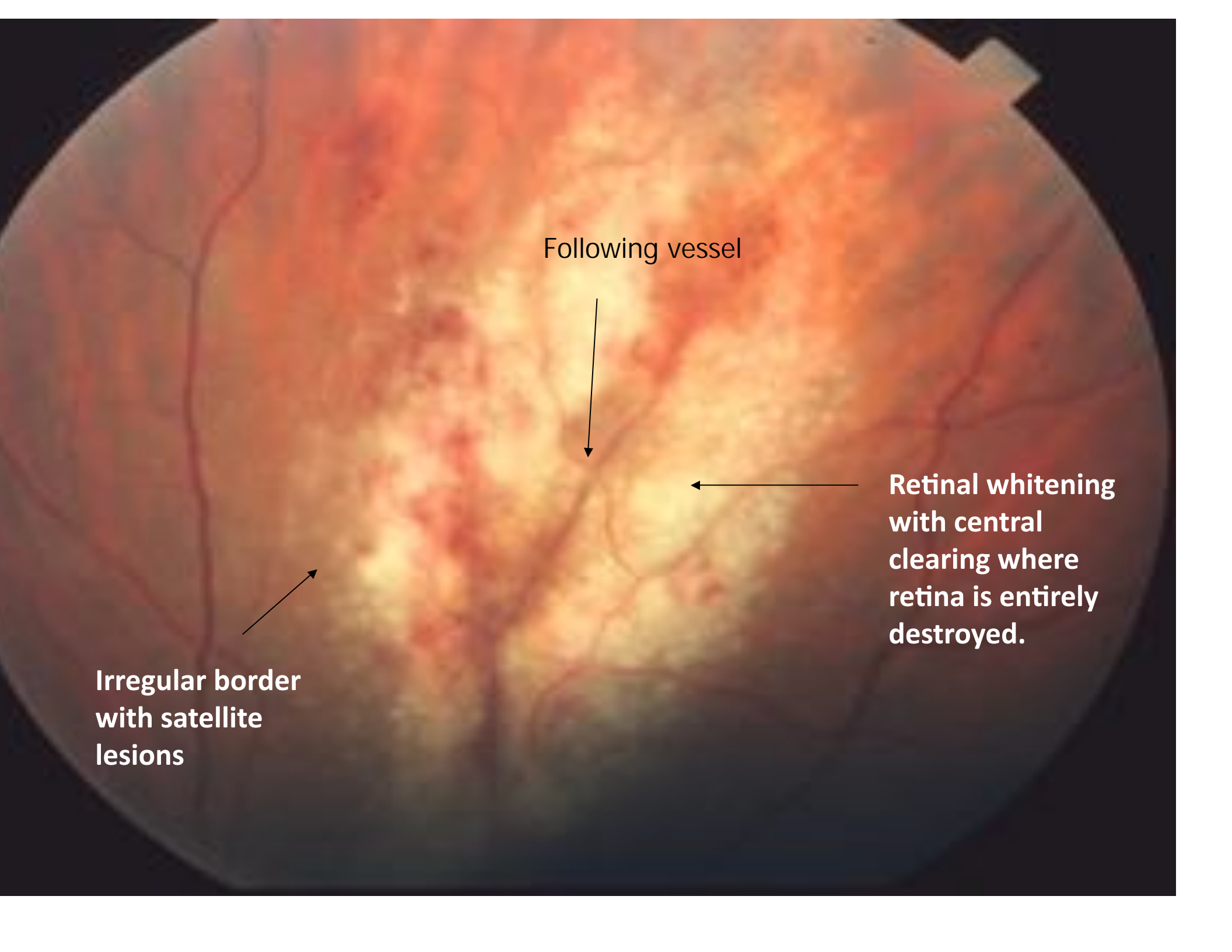
- The clinical “gold standard” is examination of the entire retina with an indirect ophthalmoscope through a dilated pupil by a skilled examiner.
- Diagnosis is based on pattern recognition

Pattern Recognition

1. Dense opaque retinal whitening
2. Irregular border with small white satellite lesions
3. Centrifugal spread with Central clearing
4. Tends to follow vessels
5. Hemorrhage, but this is highly variable



CMV retinitis



Following vessel

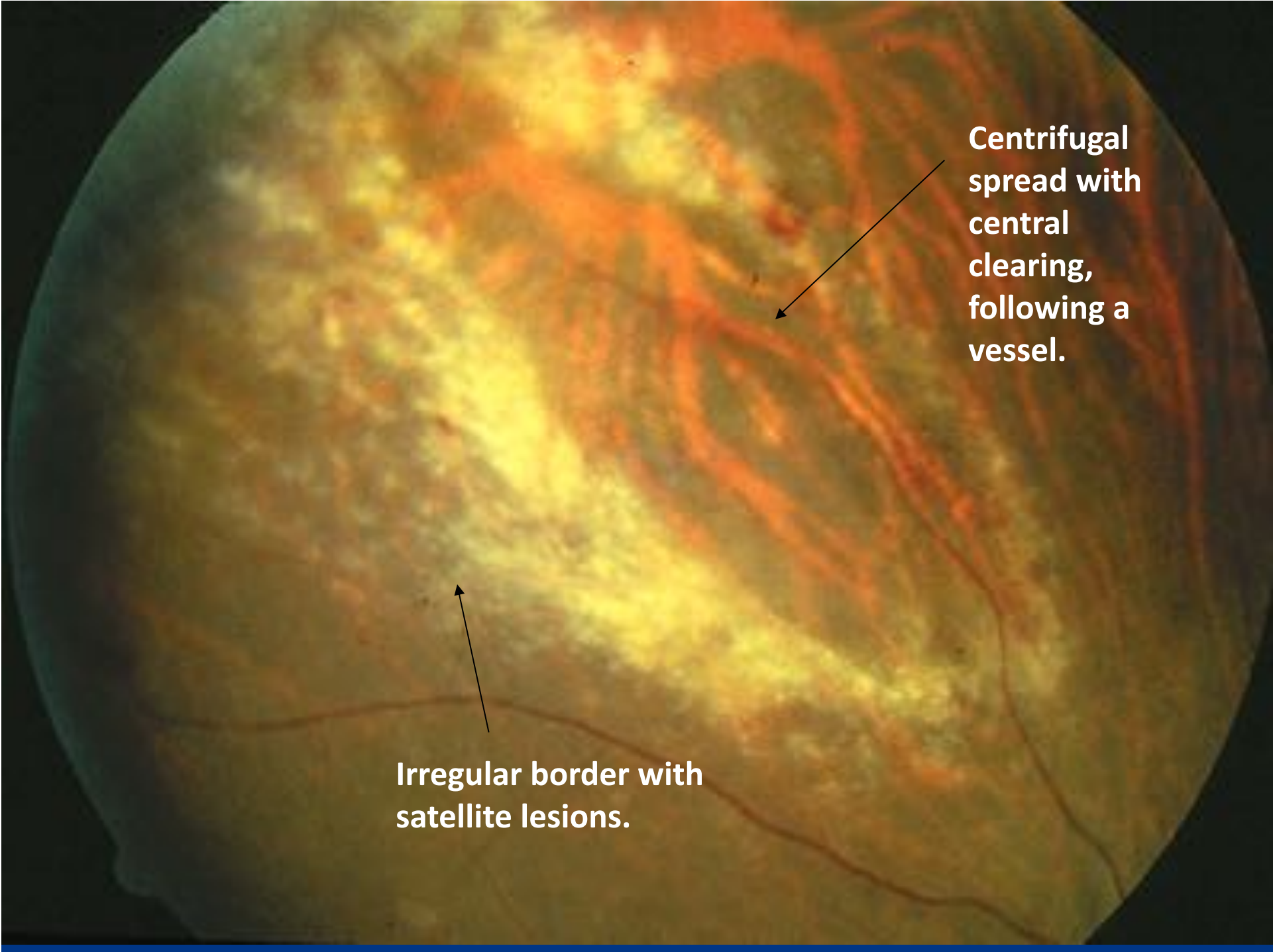


Retinal whitening with central clearing where retina is entirely destroyed.



Irregular border with satellite lesions





Centrifugal spread with central clearing, following a vessel.

Irregular border with satellite lesions.



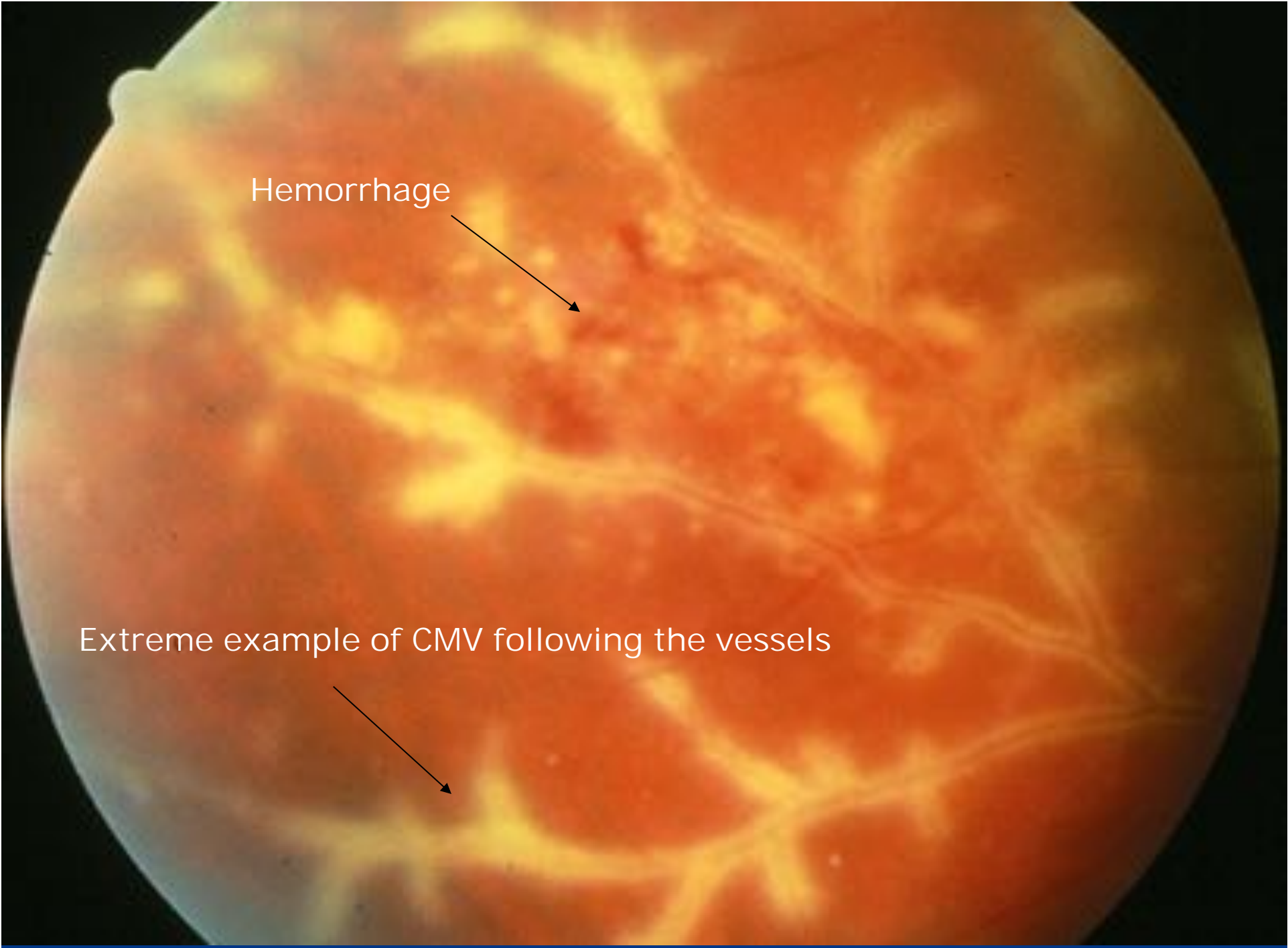
Centrifugal spread with central clearing

Tends to follow vessels

Heme common but highly variable

Dense retinal whitening

Irregular border with white satellite lesions



Hemorrhage

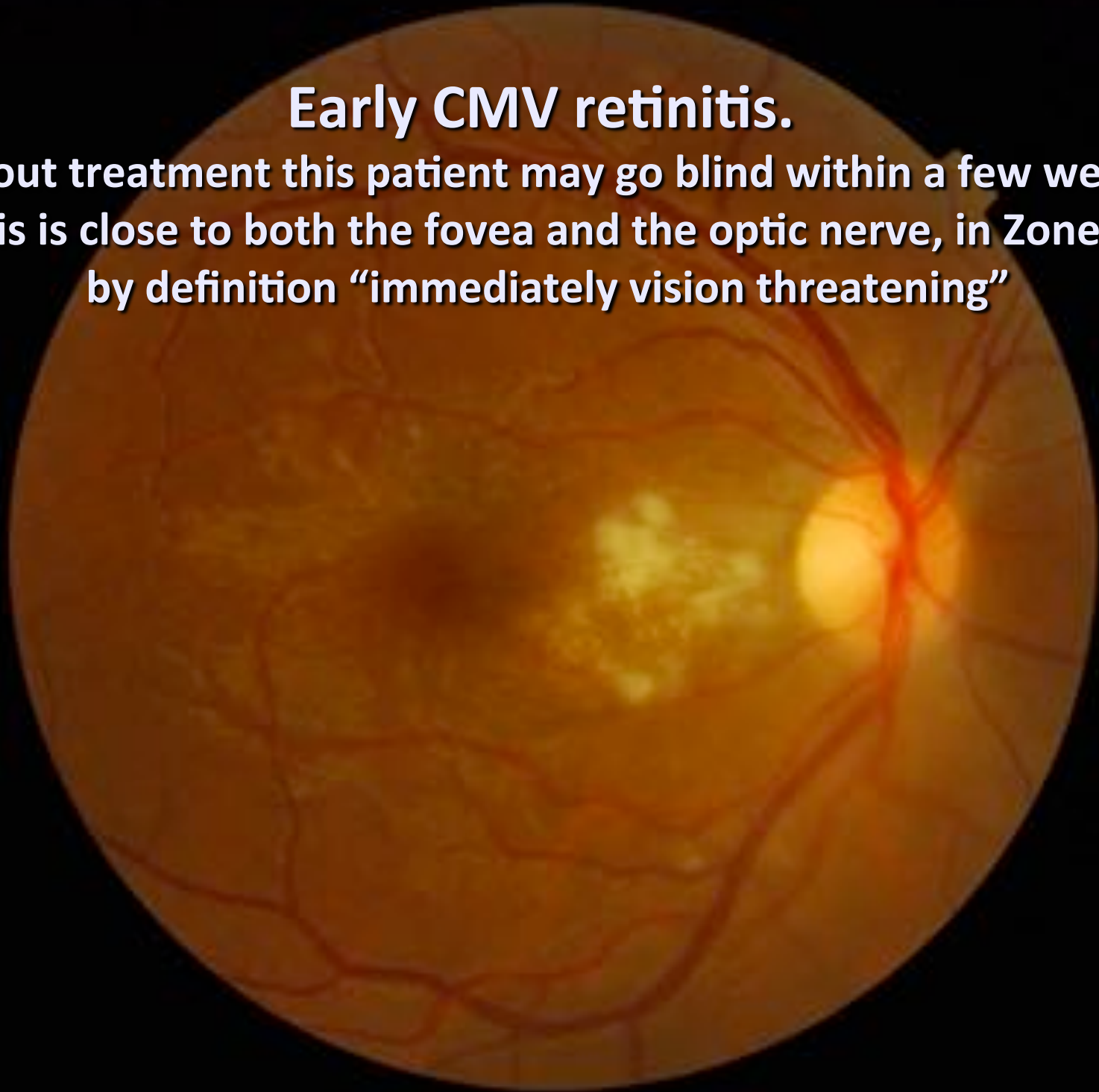


Extreme example of CMV following the vessels

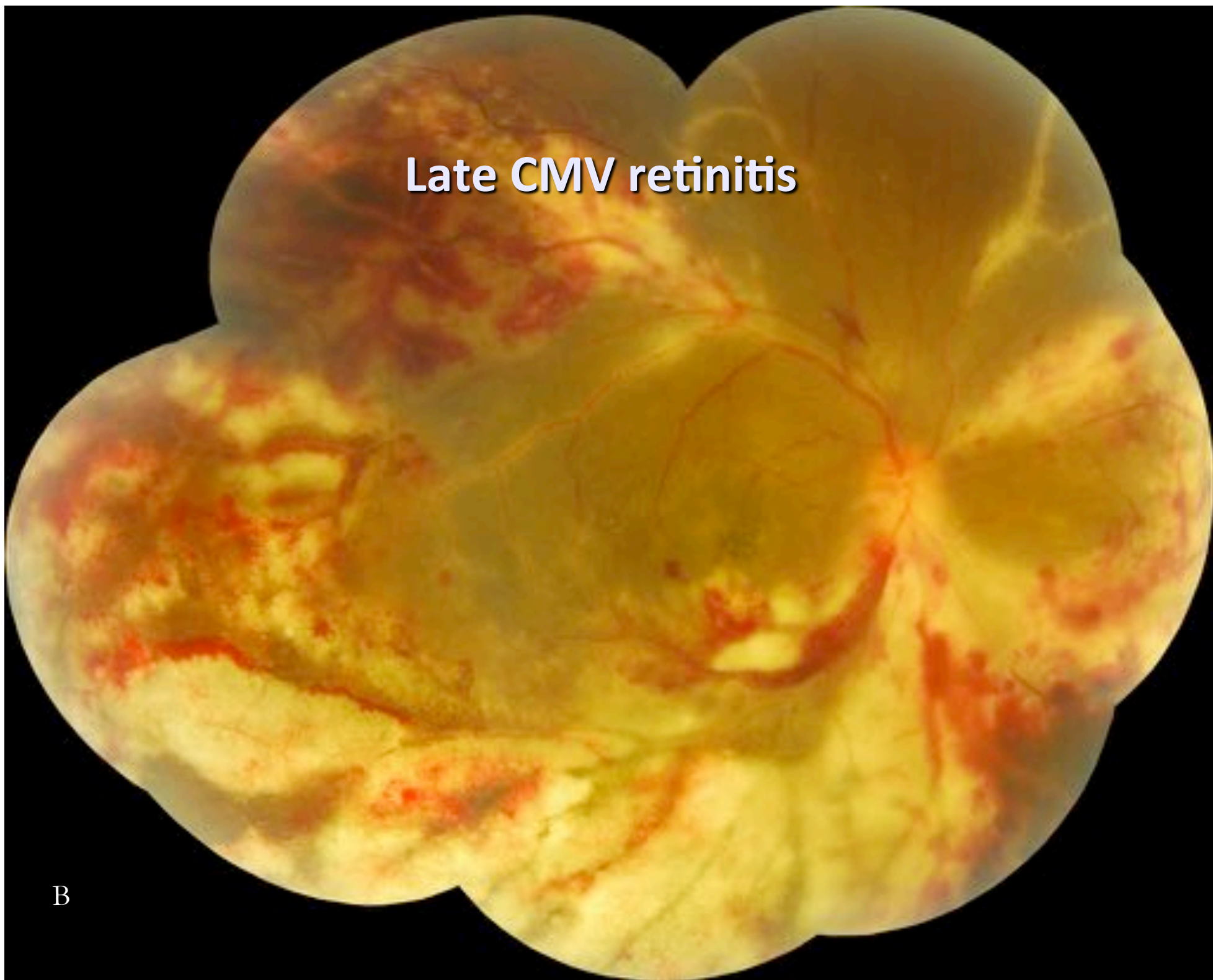


Early CMV retinitis.

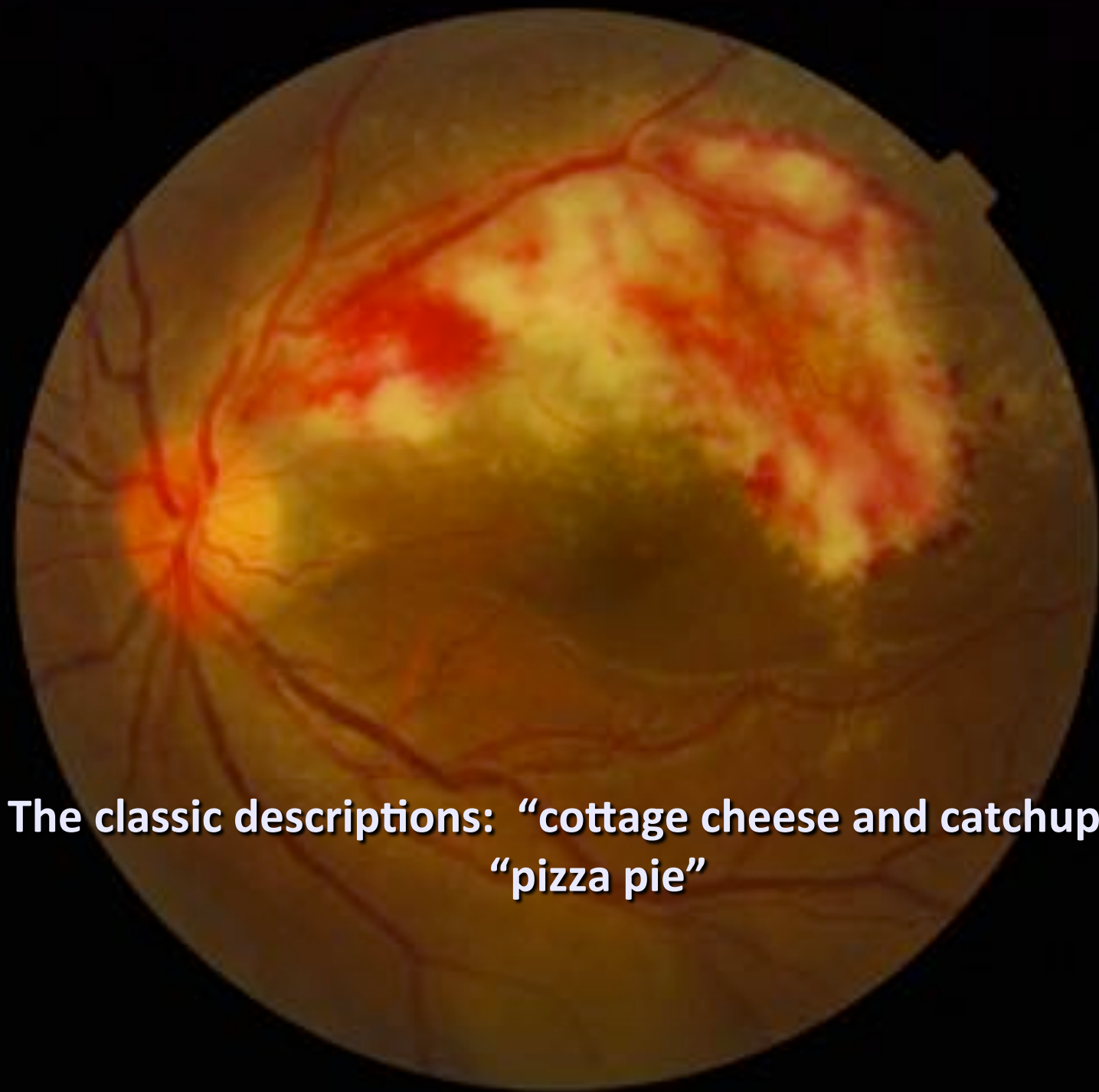
**Without treatment this patient may go blind within a few weeks.
Retinitis is close to both the fovea and the optic nerve, in Zone 1 and
by definition “immediately vision threatening”**



Late CMV retinitis



B



**The classic descriptions: “cottage cheese and catchup” or
“pizza pie”**

Do not rely on Symptoms

- CMV retinitis does not cause redness or pain.
- Characteristic symptoms include floaters, scotoma (holes in vision), photopsia (flashing lights) and blurred vision.
- Although some studies report high prevalence of symptoms, they are often discounted or ignored, leading to late presentation of disease
- A study by MSF/B in Cambodia reported 44% of patients with CMV retinitis had no symptoms.

CMV screening criteria

- CD4 <100 cells/ul
- CMV related eye complaints. (floaters, scotoma)
- Features of systematic CMV infection.
- Patients with CWS are re-examined q 3 weeks until resolved
- Patients with normal retinas re-screened 3 monthly as long as the CD4 count remains <100

A CMV retinitis project in Myanmar

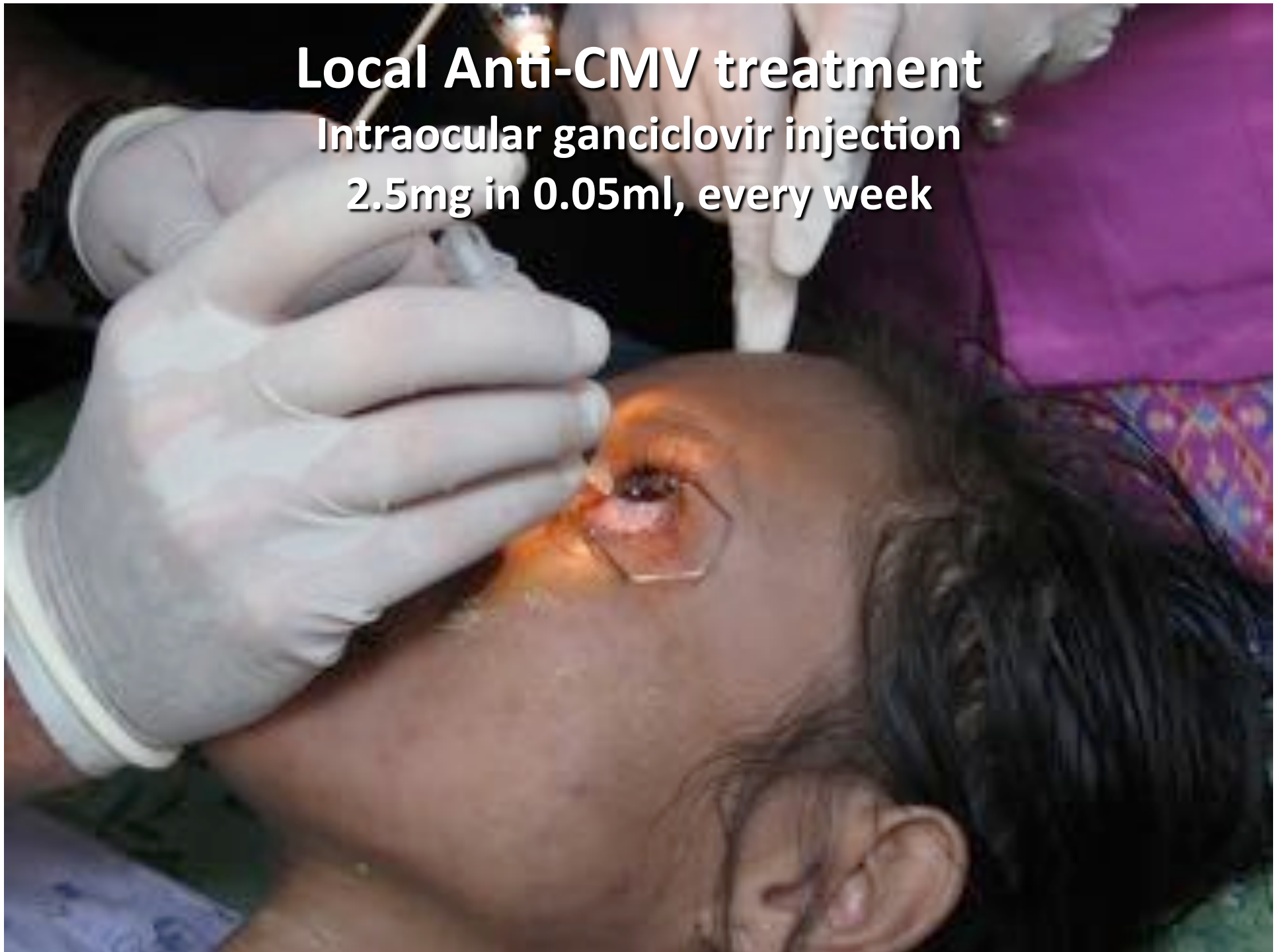- Data from 2007-2009 in 2 clinics in Yangon (7);
 - Screening was done for 891 patients
 - CMV retinitis was diagnosed in 24% (211/891).
 - Bilateral disease was present in 36% of CMV patients.
 - A total of 1296 injections were administered.
 - There was a single case of infectious endophthalmitis.
- Since 2007 till 2014 thousands of patients have been screened in 10 clinics through this project.
- Approx. 1,000 patients with CMV retinitis have been treated with intraocular injections.

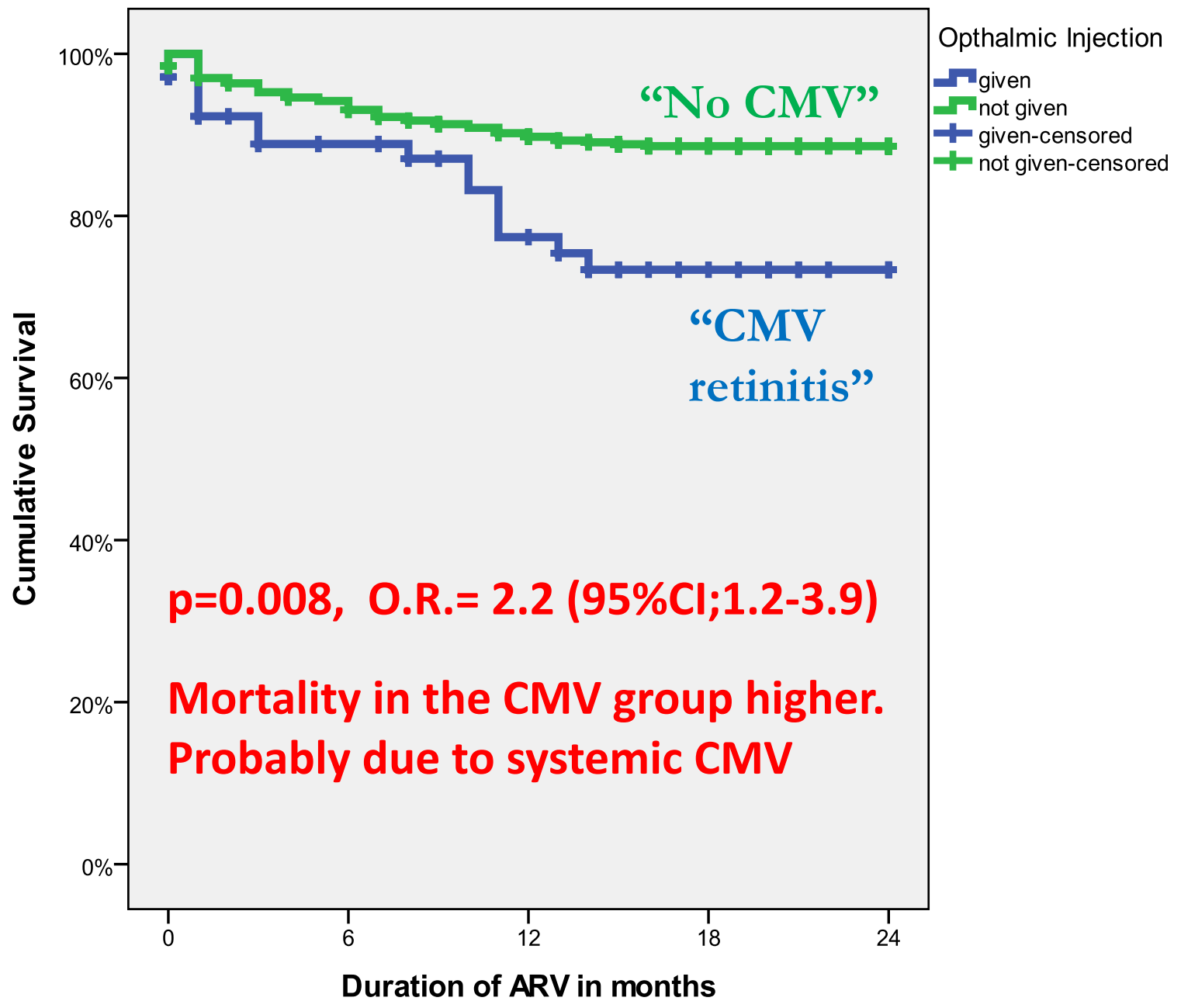
Anti-CMV Treatment

Ganciclovir administered systemically (daily intravenous infusion), or locally (intraocular injection).

Valganciclovir, a well-absorbed oral prodrug of ganciclovir, can achieve equivalent blood levels and is equally effective.

Local Anti-CMV treatment
Intraocular ganciclovir injection
2.5mg in 0.05ml, every week





- Blindness has been prevented
- But mortality remains high.

How can we decrease CMV blindness and mortality in Myanmar?

- Systematic screening of patients CD4<100
- Management of CMV retinitis at the primary care level is feasible in resource-poor settings.
- With appropriate training and support, CMV retinitis can be diagnosed and treated by AIDS clinicians (non-ophthalmologists), just like other major opportunistic infections.
- Oral valganciclovir should be made available for the treatment of CMV retinitis to prevent blindness and reduce mortality.

November 2006



November 2007



A woman with AIDS, totally blind in right eye and raging infection in left eye. Complete blindness expected soon.

One year follow up. Ganciclovir into the left eye (5x) and vision saved

References

1. Yust I, Fox Z, Burke M, Johnson A, Turner D, et al. Retinal and extra ocular cytomegalovirus end-organ disease in HIV-infected patients in Europe: a EuroSIDA study, 1994-2001. *Eur J Clin Microbiol Infect Dis*. 2004 Jun;23(7):550-9.
2. Ausayakhun S, Yuvaves P, Ngamtiphakorn S, Prasitsilp J (2005) Treatment of cytomegalovirus retinitis in AIDS patients with intravitreal ganciclovir. *J Med Assoc Thai* 88 (Suppl 9): S15-S20.
3. Ausayakhun S, Watananikorn S, Ngamtiphakorn S, Prasitsilp J (2005) Intravitreal foscarnet for cytomegalovirus retinitis in patients with AIDS. *J Med Assoc Thai* 88: 103-107.
4. Saranchuk P, Bedelu M, Heiden D. Retinal examination can help identify disseminated tuberculosis in patients with HIV/AIDS. *Clin Infect Dis* 2013; 56:310–2
5. Heiden D, Ford N, Wilson D, Rodriguez WR, Margolis TM, Janssens B, Bedelu M, Tun NN, Goemaere E, Saranchuk P, Sabapathy K, Smithuis F, Luyirika E, Drew WL. Cytomegalovirus Retinitis: The Neglected Disease of the AIDS Pandemic, *PLoS Medicine*, December 2007.
6. Ford N, Shubber Z, Saranchuk P, Pathai S, Durier N, O'Brien D, Mills EJ, Pacual F, t'Hoen E, Holland GN, Heiden D. Burden of HIV-related cytomegalovirus retinitis in resource-limited settings: a systematic review. *Clin Infect Dis*. Nov 2013;57(9):1351-1361.
7. Tun N, London N, Kyaw MK, et al. CMV retinitis screening and treatment in a resource-poor setting: three-year experience from a primary care HIV/AIDS programme in Myanmar. *J Int AIDS Soc*. 2011;14:41.
8. Ausayakhun S, Skalet AH, Jirawison C, et al. Accuracy and reliability of telemedicine for diagnosis of cytomegalovirus retinitis. *American journal of ophthalmology*. Dec 2011;152(6):1053-1058 e1051.
9. Yen M, Ausayakhun S, Chen J, et al. Telemedicine Diagnosis of Cytomegalovirus Retinitis by Nonophthalmologists. *JAMA ophthalmology*. Jun 19 2014.
10. Choeng Jirawison, MD; Michael Yen, BS;* Prattana Leenasirimakul, MD; Jenny Chen, MD; Siripim Guadanant, BA; Paradee Kunavisarut, MD; Direk Patikulsilpa, MD; Nawat Watanachai, MD; Somsanguan Ausayakhun, MD, MHSc; David Heiden, MD; Gary N Holland, MD; Todd P Margolis, MD, PhD and Jeremy D Keenan, MD, MPH Telemedicine Screening for Cytomegalovirus Retinitis at the Point of HIV Care (recently submitted to *JAMA ophthalmology*)
11. Pecorella I, Ciardi A, Credendino A, Marasco A, Di Tondo U, et al. Ocular, cerebral and systemic interrelationships of cytomegalovirus infection in a post-mortem study of AIDS patients. *Eye*. 1999 Dec;13 (Pt6):781-5.
12. Wallace JM, Hannah J. Cytomegalovirus pneumonitis in patients with AIDS. Findings in an autopsy series. *Chest*. 1987 Aug;92(2): 198-203.
13. Brantsaeter AB, Liestel K, Goplen AK, Dunlop O, Bruun JN. CMV disease in AIDS patients: incidence of CMV disease and relation to survival in a population-based study from Oslo. *Scand J Infect. Dis*. 2002; 34(1):50-55.
14. Tun NN, Smithuis F, London N, Drew WL, Heiden D. Mortality in patients with AIDS-related cytomegalovirus retinitis in Yangon, *Clinical Infectious Disease* (accepted, in press).

The end

Thank you

For further information please contact :

Jean-Marc Debricon

CEO

jm@greenshootsfoundation.org

Mobile: +44 7595 600 766

Green Shoots Foundation

P.O. Box 63678

London, SW11 9BD

UK

UK charity number 1138412

US 501(c)(3) registered

General enquiries: info@greenshootsfoundation.org

Website: www.greenshootsfoundation.org

GreenShoots
FOUNDATION